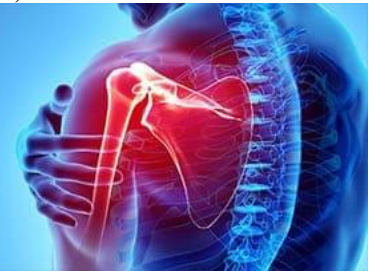


International Journal of Orthopaedics and Traumatology



ISSN Print: 2664-8318
ISSN Online: 2664-8326
Impact Factor: RJIF 5.42
IJOT 2024; 6(1): 24-27
www.orthopedicsjournal.in
Received: 19-11-2023
Accepted: 27-12-2023

Dr. Mrudev V Gandhi
Assistant Professor, GMERS
Medical College, Dharpur,
Patan, Gujarat, India

Dr. Sumit Prajapati
Assistant Professor, Nootan
Medical College & Research
Centre, Visnagar, Gujarat,
India

Dr. Maulik Patel
Senior Resident, Pacific
Hospital, Udaipur, Gujarat,
India

Dr. Vimal P Gandhi
Associate Professor, GMERS
Medical College, Dharpur,
Patan, Gujarat, India

Dr. Pragnesh S Patel
Associate Professor, GMERS
Medical College, Dharpur,
Patan, Gujarat, India

Dr. Ayush Vaishnav
Resident, GMERS Medical
College, Dharpur, Patan,
Gujarat, India

Corresponding Author:
Dr. Mrudev V Gandhi
Assistant Professor, GMERS
Medical College, Dharpur,
Patan, Gujarat, India

Evaluation of a transthecal digital nerve block for pediatric proximal phalanx injury

Dr. Mrudev V Gandhi, Dr. Sumit Prajapati, Dr. Maulik Patel, Dr. Vimal P Gandhi, Dr. Pragnesh S Patel and Dr. Ayush Vaishnav

DOI: <https://doi.org/10.33545/26648318.2024.v6.i1a.41>

Abstract

Background: Digital anesthesia in the pediatric population has traditionally been accomplished using a ring block that requires multiple injections. A modified transthecal digital nerve block is a single-injection technique of the mid-proximal phalanx that has been shown to be technically simple and highly effective in adults.

Objective: To describe the success rate of the modified transthecal digital nerve block in children.

Methods: A convenience sample of children requiring digital anesthesia for minor surgical procedures on the fingers or thumb at level of proximal phalanx at an urban tertiary-care pediatric emergency department were prospectively enrolled into the study. A transthecal digital nerve block was performed by injecting a 1:1 mixture of 1% lidocaine and 0.5% bupivacaine into the flexor tendon sheath at the mid-point between the proximal digital and the proximal inter phalangeal joint creases. The volume of anesthetic was based on age. All nerve blocks were performed by 3 investigators trained in the procedure. Successful digital anesthesia was defined as complete loss of pinprick sensation on both the dorsal and palmar aspects of the digit and the ability to complete the anticipated minor surgical procedure without pain.

Primary outcome measures were anesthesia success rate and pain score. Age appropriate pain scale scores (Face, Legs, Activity, Cry, Consol ability Scale, 0-3years; Faces Scale, 4-7years; and visual analog scale, ≥ 8 years) were recorded 5 minutes after injection. All patients were followed up for 6 months to assess for adverse events.

Results: Between November 2023 and March 2024, 48 patients (50 digits) requiring digital anesthesia were enrolled into the study. The mean age of patients was 8.3 years (median, 7.6years; range, 0.7Y17.5 years). Twenty-four (50%) were boys. Overall, the transthecal digital nerve block technique was successful in 47(94%) of the 50 digits (95% confidence interval [CI], 83%Y98%), including 37(97%) of 38 fingers (95% CI, 85% -99%) and 10 (83%) of 12 thumbs (95% CI, 54%-96%). Forty-seven (94%) of the 50 digits had a recorded pain score of 0 five minutes after injection. Mean (SD) procedure time was 113 (24.8) seconds, and mean (SD) anesthetic volume was 2.13 (0.61) mL. No adverse events were reported.

Conclusions: The single-injection modified transthecal digital nerve block is a safe and effective method for digital anesthesia in children. These data confirm the applicability of transthecal digital nerve block for children with finger and thumb injuries that require minor surgical procedures.

Keywords: Transthecal digital nerve block, regional anesthesia

Introduction

Finger injuries are common during childhood especially in rural area of India and often require minor surgical or orthopedic management. A digital anesthetic is frequently used to facilitate the completion of most of these procedures. This type of regional anesthetic is commonly prescribed by emergency physicians for fingertip injuries, laceration repair, fracture manipulation, dislocation reduction, foreign body removal and wound debridement. Traditionally, digital anesthesia for a pediatric patient is accomplished using the 2-injection ring block, initially described by Eriksson ^[1] in 1979. This technique, however, requires multiple injections and carries with it the risk of compromise of the integrity of the neurovascular bundles.

A transthecal digital nerve block was first described in adult patients in 1990 ^[2], performed via a single injection into the flexor tendon sheath. The mechanism was further anatomically defined using a cadaver to demonstrate that flexor transthecal injection of methylene blue

produced diffuse staining of the digital nerves [3].

Complete digital anesthesia success rates using the transthecal digital block have been reported to be between 91% and 99% [2, 4]. A randomized controlled trial showed that the transthecal block was clinically equal to the conventional 2-injection ring block method regarding anesthesia and visual analog pain scores [5]. In 1997, Whetzel *et al.* [6] modified the transthecal approach to improve anesthesia and simplified it by providing more readily identifiable landmarks. Toroketal [7] further modified the transthecal approach by injecting the anesthetic at the mid proximal phalanx, increasing reproducibility and translating applicability to the thumb. With the modification of Torok *et al.*, [2] complete palmar and dorsal anesthesia was achieved in 357 (99%) of 360 digits, including 52 (98%) of 53 thumbs. In all 3 failed cases, the examiner had not realized the flexor tendon sheath had been breached by the injury.

The efficacy of the modified transthecal block has not been studied in the pediatric population. Two previous studies in children describe a palmar/metacarpal head injection site [4, 8], not the mid proximal phalanx site used for the modified transthecal block. This prospective study describes the effectiveness of the modified transthecal digital block, described by Torok *et al.*, [2] in pediatric patients. We hypothesized that the modified transthecal digital block provides effective digital anesthesia in children with finger injuries requiring minor surgical or orthopedic management.

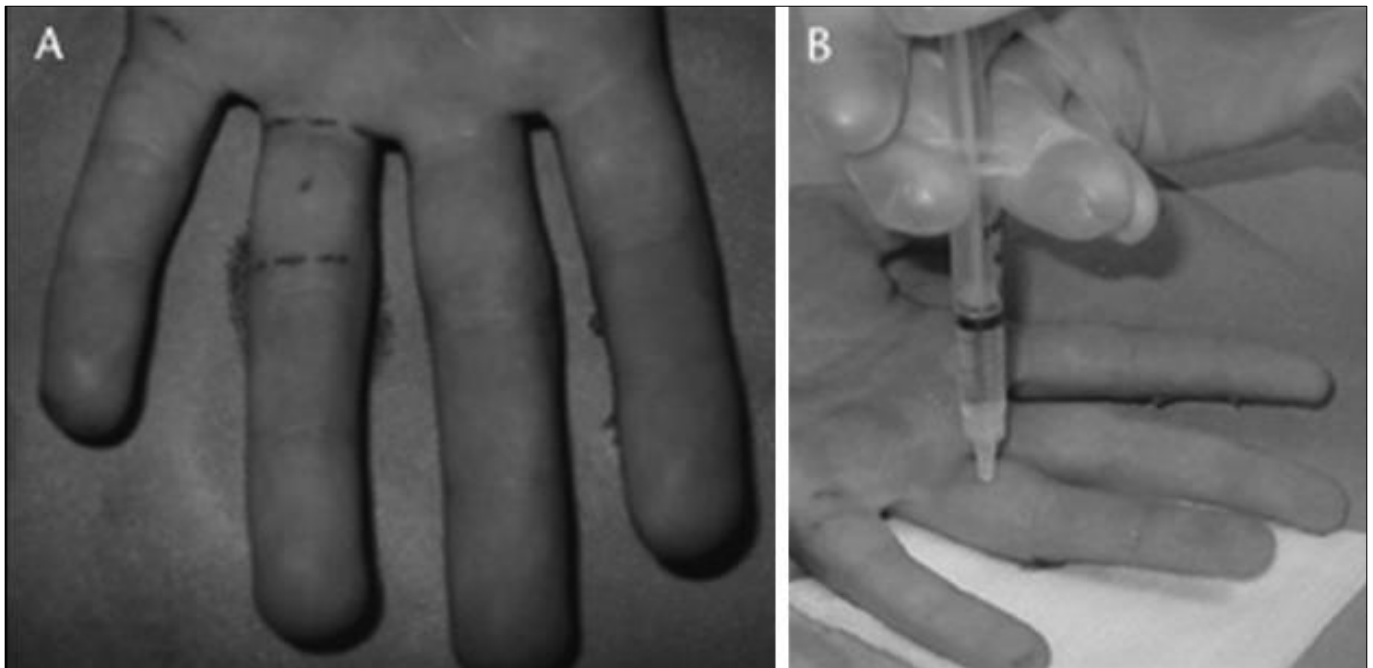
Methods

This is a prospective, descriptive study of the efficacy of a modified transthecal digital block in the child. Patients were children and adolescents, 18 years or younger, examined in

a tertiary care hospital emergency department with dorsal or palmar finger injuries distal to the proximal digital crease that required reparative procedures with local anesthesia. Procedures included laceration repairs, foreign body removal, dislocation reduction, fracture manipulation, incision of paronychia, and nail bed injuries. Exclusion criteria included open flexor tendon sheath injuries, infections of the flexor tendon sheath, lesions with an overlying superficial infection at the proposed injection site, known allergy to lidocaine or bupivacaine, hematologic or vasospastic diseases, pregnancy, or the need for procedural deep sedation.

Each parent or patient provided informed consent or assent (as appropriate for the age of the patient), respectively, before the administration of digital anesthesia and was enrolled into the study, approved by the institution's human rights committee.

The modified transthecal digital block was performed using the method described by Torok *et al.* [7] A 3-mL syringe with a 0.5-in 30-gauge needle was filled with 1.5 mL of 1% lidocaine and 1.5 mL of 0.5% bupivacaine at room temperature. The patient's finger was cleansed with povidone-iodine solution while in the supine position. The anesthetic was injected into the flexor sheath at a point halfway between the proximal digital and proximal interphalangeal joint creases. The needle was passed through the flexor tendon and to the bone and then lifted slightly off the phalanx, at which time the anesthetic was injected (Fig. 1, 2). A volume sufficient to moderately distend the skin on the palmar aspect of the proximal phalanx was injected, typically 0.75 to 3 mL, depending on the size of the thumb or finger. The principle or co-investigators performed all procedures related to an anesthetic block.



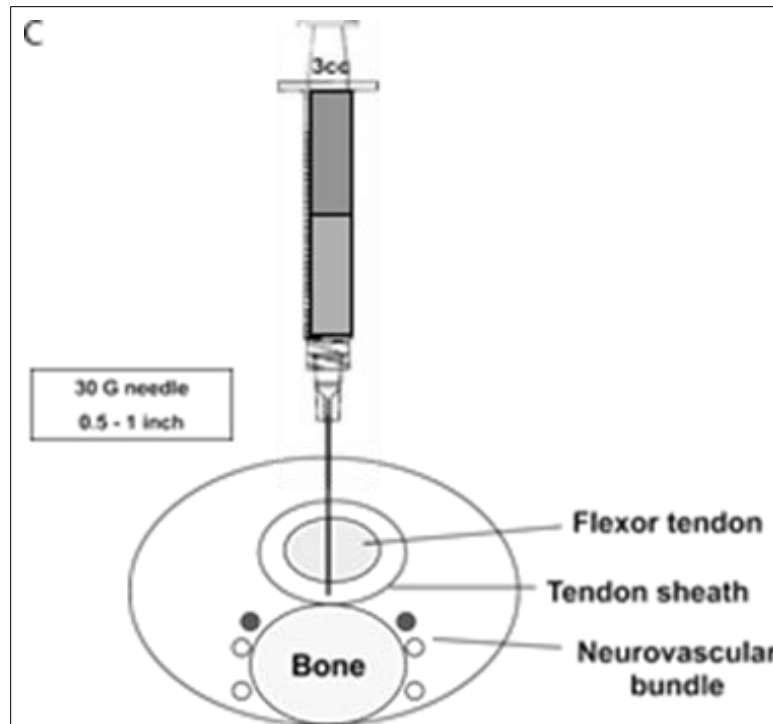


Fig 1: Digital Nerve Block

Data collected and recorded included age, sex, chief complaint, handedness, type and mechanism of injury, the total volume of anesthetic used, and the time required for infusion. The major outcome measures for the study were pain score and success of the anesthetic technique. Successful digital anesthesia was defined as loss of sensation on both the dorsal and palmar aspects of the digit as far proximally as the level of injection over the 4 predetermined areas described later and the ability to complete the proposed procedure without pain. The predetermined portions of the finger tested were (1) the eponychium, (2) the radial aspect of the skin of the finger beyond the distal inter phalangeal (DIP) joint, (3) the ulnar aspect of the skin of the finger beyond the DIP joint, and (4) the volar aspect (pad) of the fingertip beyond the DIP joint. Effectiveness of the transthecal digital nerve block was determined 5 minutes after injection. If the child continued to have pain, a reassessment was performed at 1-minute intervals for 5 additional minutes. Failure of the digital block was defined as incomplete anesthesia at 5 minutes or inability to complete the proposed procedure due to pain. Patients in this category received a second digital block using the currently accepted traditional ring block method. Our primary outcome measure, success of anesthesia at 5 minutes, was dichotomous (Yes / No).

Based on previous studies, we estimated a success rate of 90%. We calculated that 44 subjects would allow our reported rate of success to have a 95% confidence interval (CI) with a precision (bound width) of 0.15. We enrolled 48 patients (50 digits) requiring digital anesthesia to ensure the desired sample size. Descriptive statistics were used, and values presented as means with 95% CIs.

The type of pain assessment performed was dependent on the patient's age. Patients 4 years or younger were assessed using the validated Face, Legs, Activity, Cry, Consolability Scale.⁹ To ensure Face, Legs, Activity, Cry, Consolability Scale score reliability, videotape analysis was performed by an independent observer upon completion of the study. Age-specific pain assessment using validated scales was performed for children 5 to 7 years of age using the Wong-Baker FACES and the visual analog scales^[10, 11] for patients 8 to 18 years of age.

Results

Forty-eight patients were enrolled for a 6-month period from November 2023 to May 2024. Fifty digits (38 fingers and 12 thumbs) were anesthetized in 24 boys and 24 girls who had a mean age of 8.3 years. Demographic data and the indications for digital anesthesia are shown in Table 1.

Table 1: Demographics and indications for digital nerve block

Indication for Transthecal Digital Block	Number	Mean Age, Range, (SD), yr	Sex, Male, %	Dominant Hand, %
Laceration	19	11.1 (0.8Y17.1, 4.6)	57	47
Nail bed injury	19	5.9 (0.7Y17.5, 5.3)	52	63
Paronychia	6	7.8 (3Y16.6, 4.6)	50	66
Foreign body	2	6 (4.8Y7.2, 1.6)	50	50
Dislocation	1	14	100	100
Nail avulsion	1	13	0	0
Fracture reduction	1	6	0	0
Skin avulsion	1	8	0	100
Total	50	8.3 (0.7Y17.5, 5.1)	50	56

Overall, the transthecal block was successful in 47 (94%) of the 50 digits (95% CI, 83%-98%), including 37 fingers (97%; 95% CI, 85%-99%) and 10 thumbs (83%; 95% CI, 54%-96%; Table 2). Forty-seven (94%) of 50 patients had a pain score recorded as 0 at 5 minutes after injection. The mean (SD) transthecal digital block procedural time was 113 (24.8) seconds, and the mean (SD) anesthetic volume was 2.1 (0.61) mL (range, 0.75Y3 mL). The breakdown of mean volume by age is shown in Table 3.

Table 2: Transthecal digital block success rates

	Thumb	Index	Middle	Ring	Small	Total
Failure	10	11	10	9	7	47
Success	2	0	0	0	1	3

Table 3: Anesthetic volume by age

Age (yr)	No	Mean Volume ml	Range ml
0-2	7	1.3 (0.5)	0.75-0.25
3-10	24	1.9 (0.4)	1.5-2.5
>10	19	2.6 (0.3)	2.5-3

Age, yr Number Volume, Mean (SD), mL Range, mL 0Y2 7 1.3 (0.5) 0.75Y2.5 92Y10 24 1.9 (0.4) 1.5Y2.5 910 19 2.6 (0.3) 2.5Y3 Total 50 2.1 (0.6) 0.75Y3

All patients were followed up at a 48-hour visit and then by telephone at 1 and 6months.No adverse events were reported.

Discussion

The success rate of the modified transthecal block in this study was 94% overall (47/50 digits), similar to the results of several adult studies using the same technique [7, 12].

We also had success anesthetizing 10 of 12 thumbs using the single-injection technique. The thumb is notoriously difficult to anesthetize because of its complex anatomy, yet our method proved to be successful without an increased degree of difficulty. The 3 un- successful blocks were categorized as such because of incomplete blockade of both the palmar and dorsal surfaces of the finger or thumb. This study also demonstrates that the modified transthecal digital nerve block can be accomplished in under 2 minutes. Our investigators were trained using only brief observations of the technique, and hence, we feel that this method is simple and quickly learned.

Successful digital anesthesia is a challenging technical procedural skill that is frequently required in the pediatric emergency setting. It is a source of anxiety for patients, parents, and physicians. The traditional ring block has been considered the criterion standard for digital anesthesia in the pediatric population, yet several adult studies have demonstrated that more effective methods of practice are available. This study demonstrated the effectiveness of the single-injection modified transthecal digital nerve block in the injured child. This was not an equivalency study, as we did not compare this method with the traditional ring block technique. The potential advantages over the traditional ring block include ease of administration, single versus multiple injections, smaller volume of anesthetic used, and avoidance of risks to digital neurovascular bundles, including direct trauma and arterial spasm. Future studies will compare such techniques, including success rates, time to anesthesia, and pain at the time of injection. Furthermore, since the completion of the study, the authors have maintained similar success rates using 1% lidocaine alone, without the addition of 0.5% bupivacaine. This will also be evaluated in future studies.

Conclusion

The modified transthecal digital nerve block was performed successfully in 94% of the pediatric patients in this study. The transthecal approach is simple, rapid, and safe and a highly effective anesthetic technique for children with finger injuries especially of proximal phalanx, providing an attractive alternative to the conventional 2-injection ring block technique that has previously been considered a standard technique.

Conflict of Interest

Not available

Financial Support

Not available

References

- Eriksson E. Illustrated Handbook of Local Anesthesia. London, UK: Lloyd-Luke; c1979.
- Chiu DT. Transthecal digital block: flexor tendon sheath used for anesthetic infusion. *J Hand Surg.* 1990;15(3):471-477.
- Sarhadi NS, Shaw-Dunn J. Transthecal digital nerve block: an anatomical appraisal. *J Hand Surg.* 1998;23(4):490-493.
- Morrison WG. Transthecal digital block. *Arch Emerg. Med.* 1993;10(1):35-38.
- Hill RG Jr, Patterson JW, Parker JC, *et al.* Comparison of transthecal digital block and traditional digital block for anesthesia of the finger. *Ann Emerg. Med.* 1995;25(5):604-607.
- Whetzel TP, Mabourakh S, Barkhordar R. Modified transthecal digital block. *J Hand Surg.* 1997;22(2):361-363.
- Torok PJ, Flinn SD, Shin AY. Transthecal digital block at the proximal phalanx. *J Hand Surg.* 2001;26(1):69-71.
- Castellanos J, Ramirez C, De Sena L, *et al.* Transthecal digital block: digital anesthesia through the sheath of the flexor tendon. *JBJS Br.* 2000;82:889.
- Merkel SI, Voepel-Lewis T, Shayevitz JR, *et al.* The FLACC: A behavioral scale for scoring postoperative pain in young children. *Pediatr. Nurs.* 1997;23:293-297.
- Wong D, Baker C. Pain in children: comparison of assessment scales. *Pediatr. Nurs.* 1988;14(1):09-17.
- Chapman CR, Case KL, Dubner R, *et al.* Pain measurement: an overview. *Pain.* 1985;22:21-31.
- Low CK, Wong HP, Low YP. Comparison between single injection transthecal and subcutaneous digital blocks. *J Hand Surg.* 1997;22(5):582-584.

How to Cite This Article

Gandhi MV, Prajapati S, Patel M, Gandhi VP, Patel PS, Vaishnav A. Evaluation of a transthecal digital nerve block for pediatric proximal phalanx injury. *International Journal of Orthopaedics and Traumatology.* 2024; 6(1): 24-27.

Creative Commons (CC) License

This is an open access journal, and articles are distributed under the terms of the Creative Commons Attribution-NonCommercial-ShareAlike 4.0 International (CC BY-NC-SA 4.0) License, which allows others to remix, tweak, and build upon the work non-commercially, as long as appropriate credit is given and the new creations are licensed under the identical terms.